

ORIGINAL ARTICLE

A silver–alginate-coated dressing to reduce peripherally inserted central catheter (PICC) infections in NICU patients: a pilot randomized controlled trial

ML Hill¹, L Baldwin¹, JC Slaughter², WF Walsh¹ and J-H Weitkamp¹

¹Division of Neonatology, Department of Pediatrics, Vanderbilt University School of Medicine and Monroe Carell Jr Children's Hospital at Vanderbilt, Nashville, TN, USA and ²Department of Biostatistics, Vanderbilt University Medical Center, Nashville, TN, USA

Objective: Our aim was to evaluate the safety of a silver–alginate-containing dressing to reduce peripherally inserted central catheter (PICC) infections in neonatal intensive care unit (NICU) patients.

Study Design: Patients were randomized 3:1 to receive a patch containing silver, alginate and maltodextrin or standard of care. Patches were placed under the regular transparent retention dressing at the PICC exit site at insertion and were replaced with every dressing change at least every 2 weeks until PICC discontinuation. All study infants were monitored for adverse skin reactions.

Result: A total of 100 infants were followed up for 1922 person-days, including 75 subjects with 89 PICCs who received the patch. The median birth weight (1330 g) and median gestational age (30 weeks) was lower in the patch group when compared with the controls ($P=0.001$ and 0.005 , respectively). Study patients received the patch with their PICC at a median age of 5 days; the patch stayed in place for a median of 13 days. We noted no adverse skin reactions and found no evidence that the patch alters the microbiology of PICC-associated infections.

Conclusion: This pilot trial suggests that silver–alginate-coated dressings are skin safe and their inclusion in future trials aimed at reduction of PICC-associated bloodstream infections in the NICU should be considered.

Journal of Perinatology (2010) **30**, 469–473; doi:10.1038/jp.2009.190; published online 10 December 2009

Keywords: infants; premature; sepsis; catheter-related infections; health-care-associated infections; silver compounds

Introduction

Peripherally inserted central catheters (PICCs) are broadly used for vascular access in the neonatal intensive care unit (NICU) for nutrition and administration of medications. At least 46% of very low birth weight (VLBW) infants receive a PICC at some point in their hospital stay.¹ Central lines, such as a PICC, disrupt the skin's integrity, making infection with bacteria and fungi possible. It is estimated that 42% of VLBW infants with a PICC in place for ≥ 22 days will have one or more events of late-onset sepsis.¹ The consequences of infection include increased days of hospitalization and mechanical ventilation, increased risk of mortality and a higher incidence of poor neurodevelopmental outcome.^{1,2}

Antiseptic- or antimicrobial-impregnated patches or dressings have been developed to reduce central venous catheter infections. Chlorhexidine-impregnated sponges reduced the risk of infection in adult ICU patients,³ and their inclusion in central venous catheter maintenance bundles was successful and cost effective in pediatric ICUs.^{4,5} Unfortunately, chlorhexidine-impregnated sponges were not effective in NICU patients and caused pressure necrosis, scarring or severe sponge-associated contact dermatitis in >15% of VLBW infants.⁶

Ionic silver has broad antimicrobial activity and is being used in catheters and cuffs to prevent central line infections in adult ICU patients. Development of these products for use in premature infants has been hindered, because silver-containing products can cause permanent skin color change in this population. We designed a pilot randomized controlled trial to test the skin safety of a sterile patch of polyurethane foam coated with ionic silver, alginate and maltodextrin matrix in NICU patients. The patch combines the absorptive and hemostatic properties of alginates with the phagocyte-attracting attributes of maltodextrin and the bactericidal effects of silver ions. The patch does not interfere with imaging modalities, including magnetic resonance imaging, and is approved by the Food and Drug Administration for prevention of catheter-related infections. However, there are no published studies to support its safety or effectiveness in NICU patients.

Correspondence: Dr J-H Weitkamp, Division of Neonatology, Monroe Carell Jr Children's Hospital at Vanderbilt, 2215 B Garland Avenue, 1125 MRB IV/Light Hall, Nashville, TN 37232-0656, USA.

E-mail: hendrik.weitkamp@vanderbilt.edu

Received 22 July 2009; revised 5 October 2009; accepted 2 November 2009; published online 10 December 2009

Methods

Study design

We conducted a single-center, prospective, randomized controlled trial to assess the skin safety of patches containing silver, alginate and maltodextrin (Algidex DeRoyal, Inc., Powell, TN, USA) that were placed on PICC exit sites in NICU patients. The Vanderbilt institutional review board approved the study and written parental informed consent was obtained before infants were enrolled. The patch is approved by the Food and Drug Administration as a bacterial barrier to help prevent catheter-related infections. The product calls for replacement of the patch with weekly dressing changes. The delicate skin of premature infants and the risk for PICC displacement and/or infection has led some to recommend that the initial dressing should not be replaced unless the exit site is soiled or shows compromised integrity.⁷ For this study, we placed the patch under the standard transparent retention dressing at the PICC exit site at the time of PICC insertion and replaced it with every dressing change at least every 2 weeks until the PICC was discontinued. The patch was only used for peripherally inserted PICCs, and not for umbilical or surgical central lines.

Study patients

From June 2008 to February 2009, we recruited patients at the Monroe Carell Jr Children's Hospital at Vanderbilt NICU who were scheduled to have a PICC placed. Infants were considered eligible if they were admitted for a minimum of 72 h and a guardian was available to give informed consent. Infants were declared ineligible if they already had a central line in place (including umbilical lines), if there was a pre-existing skin condition or discoloration or if written informed consent could not be obtained. In case a second central vascular access catheter (PICC or surgical line) was placed during the study, data collection was ended the day the second line was inserted. The study participants were randomly assigned in a ratio of 3:1 to a study or control group. A statistician assigned a status to each study number and envelopes containing the status were assembled unknown to the principal investigator and study nurse. After each patient was enrolled, the envelope with the number corresponding to order of enrollment was opened and the patient was placed in their assigned group.

Intervention

PICC placement. A separate informed consent was obtained for PICC placement and a specialized proceduralist inserted 95% of the study PICCs and performed all dressing changes. Neonatal nurse practitioners placed the remaining six PICCs, all of which were in the patch group. All PICCs were inserted under maximum sterile barrier precautions (cap, mask, sterile gown, sterile gloves and large sterile drape). Right-sided and basilic veins were preferred for access. The infant was appropriately restrained and received non-pharmacologic comfort measures, pain medication or sedation as needed. The clean skin was disinfected initially with three swab

sticks saturated with 10% povidone–iodine (Aplicare Inc., Meriden, CT, USA), which was allowed to dry before it was washed off through application of 2% alcoholic-based chlorhexidine gluconate (ChlorPrep One-Step, Cardinal Health Inc., Leawood, KS, USA) over 30 s using side-to-side motion. The catheter used was a 2-French 24-Gauge Neonatal Silicone PICC (Vygon Inc., Norristown, PA, USA), which requires an intact cannula insertion technique. The tip of the catheter was positioned at the superior vena cava/right atrial junction or the inferior vena cava at the level of the diaphragm. Catheter tip placement was verified radiographically after injection of water-soluble contrast medium. To prevent migration, the catheter was secured with Steri-Strip (3M Health Care, St Paul, MN, USA) a few millimeters from the insertion site.

Dressing. If the patient was assigned to the study group, an Algidex Ag I.V. PATCH Silver Alginate Catheter Dressing ($\frac{3}{4}$ inch disc with 2 mm opening, DeRoyal Inc.) was placed on the skin exit site of the catheter and secured with a single Steri-Strip (3M Health Care, Figure 1). The patch, the extraluminal catheter and the catheter exit site were covered by a sterile transparent polyurethane insertion site dressing (Tegaderm Film, 3M Health Care). If the patient was assigned to the control group, the same dressing was applied, but without the patch.

Dressing change. In both groups, the dressing was changed every 14 days. Used patches were replaced with new patches in the

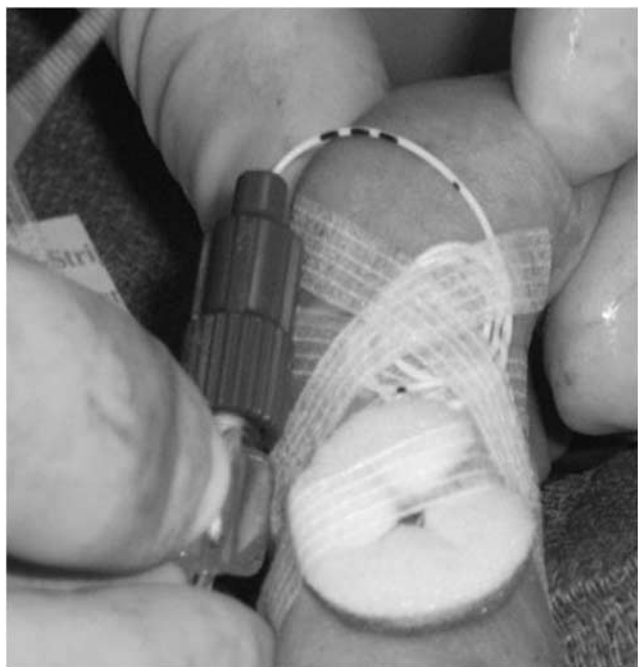


Figure 1 Photograph illustrating application of the ionic silver, alginate and maltodextrin matrix patch (Algidex, DeRoyal Inc.) over the peripherally inserted central catheter (PICC) insertion site, before placement of the transparent dressing.

study group only. If a patient was considered clinically unstable, the dressing change was moved to the next day. In case the PICC exit site was soiled with blood or concerns for compromised integrity of the dressing were raised, dressings were changed before the 14 days had passed. If a PICC had to be replaced in a study group patient, a new patch was used in the same way as at the time of initial PICC placement. Patients randomized to the control group received the standard dressing without the patch. Before dressing change, the exterior surface of the dressing and adjacent skin were cleaned with 2% alcoholic-based chlorhexidine gluconate (ChlorPrep One-Step) over 30 s using side-to-side motion. The disinfectant was allowed to dry while maximum barrier precautions were prepared. The transparent dressing and old patch were removed, followed by placement of a new patch and dressing as described above.

Skin evaluation

To assess skin safety, the bedside nurse evaluated the skin under the transparent dressing at least twice daily and documented any signs of redness, swelling or discoloration.

In addition, the skin underneath the patch was thoroughly examined at every dressing change for signs of redness, swelling or discoloration.

Statistical analysis

We used an unbalanced design in which 75 subjects were randomly assigned to the treated patch group and 25 subjects to the control group. Allocating more subjects to receive the treatment allowed us to estimate safety in the study group, which was our primary outcome, with more precision. Because we were only able to enroll a total of 100 subjects, our power to detect a clinically important difference between treatment and control (secondary endpoint) was low, regardless of the allocation proportions. We used survival analysis methods to compare the percentage of subjects who were infection free over time in the treatment and control groups. Infants were considered at risk starting from the time that the PICC was inserted and contributed information until they either had an infection or were censored due to having their PICC removed. Some infants received multiple patches during the study, but for purposes of all presented analyses, these repeated measures were treated as independent observations.

Results

Patients and catheters

During the study period, 329 patients in the Vanderbilt NICU received a PICC for vascular access. Of these, 223 patients were excluded, either because they already had a central line or for lack of written parental consent (Figure 2). After enrollment, we excluded six patients before randomization because either their PICC was discontinued or they left the NICU within <72 h of PICC

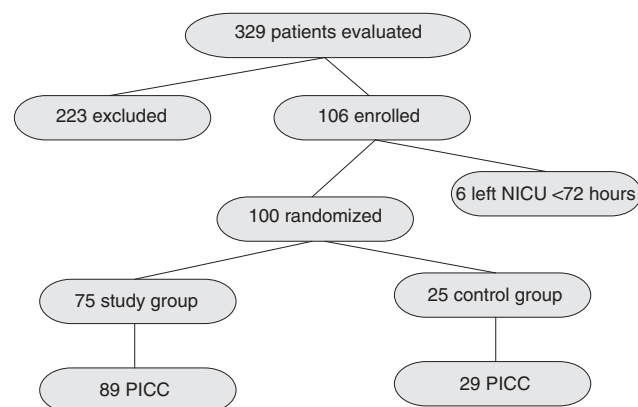


Figure 2 Flowchart of patients through the study.

Table 1 Characteristics of the study population

	Study group (n = 89)	Control group (n = 29)	P- value
Patients	75	25	NA
Male	54%	76%	0.04 ^a
Gestational age (weeks)	28 30 34 ^b	29 36 38	0.003 ^c
Birth weight (g)	980 1330 2040	1260 2450 3190	0.001 ^c
Weight at PICC placement (g)	1150 1540 2457	1520 2490 3540	0.005 ^c
Age when PICC placed (days)	3 5 18	2 4 10	0.38 ^c
Age when PICC was removed (days)	14 22 45	9 18 35	0.10 ^c
PICC days	8 13 22	5 10 18	0.11 ^c
<i>Number of PICC placed</i>			0.85 ^a
1	74%	79%	
2	21%	17%	
3	4%	3%	
<i>Number of dressing changes</i>			0.87 ^a
0	55%	62%	
1	28%	21%	
2	9%	10%	
>2	8%	7%	

Abbreviations: NA, not applicable; PICC, peripherally inserted central catheter.

^aPearson's test.

^bLower quartile, median and upper quartile.

^cWilcoxon's test.

placement. Two patients received a second central line after enrollment and data collection was stopped the day the second line was inserted. Of 100 infants who completed the study, 16 received two and two patients received three PICCs. The reasons for multiple PICC placements were infection or suspected infection ($n = 7$), PICC malfunction ($n = 6$) or renewed central line requirement ($n = 5$). The study population characteristics are shown in Table 1. Despite computerized randomization, subjects in the study group had a significantly lower gestational age ($P = 0.005$) and

Table 2 Microbiology of PICC-associated bloodstream infections

Pathogen	Patch group (n = 89) ^a	Control group (n = 29) ^b
<i>Coagulase-negative Staphylococci</i>	10 (11.2%)	3 (10.3%)
<i>Klebsiella pneumoniae</i>	1 (1.1%)	1 (3.4%)
<i>Pseudomonas aeruginosa</i>	1 (1.1%)	0
<i>Enterococcus spp.</i>	1 (1.1%)	0
<i>Escherichia coli</i>	0	1 (3.4%)
<i>Candida parapsilosis</i>	0	1 (3.4%)
Total PICC-associated blood stream infections ^c	11 (12.4%)	5 (17.2%)

Abbreviation: PICC, peripherally inserted central catheter.

^aSeventy-five patients received 89 PICCs.

^bTwenty-five patients received 29 PICCs.

^cTwo patients in the patch group and one patient in the control group grew two microbacterial organisms in blood culture during a single PICC-associated infection episode.

birth weight ($P = 0.001$) than subjects assigned to the control group. Among the study cohort, there were a total of 21 infants of <28 weeks of gestational age; 18 in the patch group and 3 in the control group. Nineteen patients in the patch group were extremely LBW (<1000 g) infants. In all, 2, 10 and 18 infants in the patch group had birth weights of <500, <750 and <1,000 g, respectively. The median number of PICC days, number of PICCs placed and number of dressing changes were similar between groups (Table 1).

A total of three patients died during the study; two were in the study group and one was in the control group. One patient in each group was withdrawn from life support because of fatal multiorgan failure associated with necrotizing enterocolitis; blood cultures were negative within 48 h of death. One extremely LBW infant in the study group with severe chronic lung disease and pulmonary hypertension died as a result of *Pseudomonas aeruginosa* pneumonia and sepsis. No death was considered an adverse event associated with the silver–alginate patch. We did not observe any adverse skin changes or any other adverse events associated with the patch in the treatment group.

We collected pilot data on the effectiveness of the patch in reducing PICC-associated bloodstream infections. Although subjects who received the patch had lower birth weight and gestational age compared with the control group, we did not detect a statistically significant difference in infection rates between groups. The predominant organism was *coagulase-negative Staphylococcus* in both groups (Table 2), indicating that the patch did not alter the microbiology of PICC-associated bloodstream infections.⁷

Discussion

Antiseptic- or antimicrobial-impregnated patches or dressings have been successfully implemented in adult ICUs to reduce central

line-associated infections.³ In NICU patients, similar efforts have been hampered by adverse skin reactions to these devices, predominantly in infants of <28 weeks of gestation. One randomized, controlled study involving 705 neonates using a chlorhexidine-impregnated sponge at the skin exit site reported no difference in the rates of PICC infections but an association with pressure necrosis, scarring or severe localized contact dermatitis, particularly in VLBW infants.⁶

A newer generation of antiseptic dressings contains antimicrobial silver compounds. The most common side effect of silver-containing products is skin color change, which can be permanent. Notably, we did not observe any noticeable skin changes with the patches containing silver, alginate and maltodextrin in infants as small as 340 g birth weight. This confirms preliminary data previously reported from a smaller trial (50 patients) using the same patch at a different institution.⁸ In that study, central line dressings were changed weekly and no adverse skin reactions were noted. We found weekly dressing changes as impractical, given the large number of patients with PICCs. In addition, unnecessary dressing changes increase the risk for catheter migration and may introduce infection. On the other hand, in view of the historic experience with previous devices and concern about skin safety, we opted to inspect the skin underneath the patch after every 2 weeks. In addition, a dressing change on an 'as needed' basis alone would have resulted in a more heterogeneous study design. Now that the skin safety of the patch has been established, dressing changes on an 'as needed' basis only can be incorporated in the design of future trials.

One limitation of this study is that we did not measure silver levels in the study group. Although silver can be absorbed from the skin, there is very little information about health effects after skin contact with silver compounds.⁹ Preliminary data from a pilot trial at a different institution found mildly elevated but not concerning silver levels in VLBW infants who received the Algidex patch.⁸ Given the theoretically higher tendency for premature skin to absorb silver, future trials using silver-containing products in VLBW infants should include measurement of silver levels and correlation with long-term neurodevelopmental outcomes.

We chose the 3:1 randomization design to detect adverse event rates with more precision in the study group.¹⁰ With 89 subjects randomized to the patch, we can conclude with 95% confidence that the true adverse event rate is <3.3% for the study group. We did not expect the unintentional randomization of more premature infants to the study group. Gestational age and birth weight both correlated inversely with risk for late-onset sepsis.¹ Despite the presumed increased risk, infection rates were lower in the study group, although the numbers did not reach statistical significance. On the basis of the results of this pilot study, a future randomized controlled efficacy trial will require approximately 132 subjects in each group to have sufficient power to detect statistical differences between study and control groups.

Bloodstream infections associated with PICC are thought to have multiple etiologies, including hub colonization, catheter adherence and biofilm development, lack of enteral nutrition, maternal separation and early life stress.^{11–14} It is therefore unlikely that addressing extraluminal migration from colonized skin alone will eradicate PICC-associated infections. Rather, a comprehensive approach that includes evidence-based care bundles is likely required to achieve this goal.^{15–19} Given the observed skin safety and trend toward reduced infection rate, future trials and quality improvement programs that are aimed at reduction of central line infections in the NICU should consider inclusion of this intervention.

Conflict of interest

The authors declare no conflict of interest.

Acknowledgments

We thank the Vanderbilt NICU Research Fund for generous support of the study and DeRoyal, Inc. for providing the study patches. We also thank the Vanderbilt NICU nursing and physician staff members for their support of this project and Steven Steele for his assistance with data retrieval. We are grateful to Judy Aschner for review of this paper and helpful discussions.

References

- 1 Stoll BJ, Hansen N, Fanaroff AA, Wright LL, Carlo WA, Ehrenkranz RA *et al*. Late-onset sepsis in very low birth weight neonates: the experience of the NICHD Neonatal Research Network. *Pediatrics* 2002; **110**: 285–291.
- 2 Stoll BJ, Hansen NI, Adams-Chapman I, Fanaroff AA, Hintz SR, Vohr B *et al*. National Institute of Child Health and Human Development Neonatal Research Network. Neurodevelopmental and growth impairment among extremely low-birth-weight infants with neonatal infection. *JAMA* 2004; **292**: 2357–2365.
- 3 Timsit JF, Schwebel C, Bouadma L, Geffroy A, Garrouste-Orgeas M, Pease S *et al*. Chlorhexidine-impregnated sponges and less frequent dressing changes for prevention of catheter-related infections in critically ill adults: a randomized controlled trial. *JAMA* 2009; **301**: 1231–1241.
- 4 Costello JM, Morrow DF, Graham DA, Potter-Bynoe G, Sandora TJ, Laussen PC. Systematic intervention to reduce central line-associated bloodstream infection rates in a pediatric cardiac intensive care unit. *Pediatrics* 2008; **121**: 915–923.
- 5 Ho KM, Litton E. Use of chlorhexidine-impregnated dressing to prevent vascular and epidural catheter colonization and infection: a meta-analysis. *J Antimicrob Chemother* 2006; **58**: 281–287.
- 6 Garland JS, Alex CP, Mueller CD, Otten D, Shivpuri C, Harris MC *et al*. A randomized trial comparing povidone-iodine to a chlorhexidine gluconate-impregnated dressing for prevention of central venous catheter infections in neonates. *Pediatrics* 2001; **107**: 1431–1436.
- 7 Cartwright DW. Central venous lines in neonates: a study of 2186 catheters. *Arch Dis Child Fetal Neonatal Ed* 2004; **89**: F504–F508.
- 8 Khattak AZ, Ross RE, Arnold C, Tiffany N, Shoemaker CT. A randomized controlled trial of the safety of silver alginate (Algidex) patches in very low birth weight (VLBW) infants with central lines. *Annual Meeting of the American Pediatric Society and Society for Pediatric Research, Hawaii, May 2008: 284*. (abstract 665).
- 9 Agency for Toxic Substances and Disease Registry (ATSDR). Toxicological Profile for Silver. www.atsdr.cdc.gov/toxprofiles/phs146.html.
- 10 Eypasch E, Lefering R, Kum CK, Troidl H. Probability of adverse events that have not yet occurred: a statistical reminder. *BMJ* 1995; **311**: 619–620.
- 11 Garland JS, Alex CP, Sevallius JM, Murphy DM, Good MJ, Volberding AM *et al*. Cohort study of the pathogenesis and molecular epidemiology of catheter-related bloodstream infection in neonates with peripherally inserted central venous catheters. *Infect Control Hosp Epidemiol* 2008; **29**: 243–249.
- 12 Costa SF, Miceli MH, Anaissie EJ. Mucosa or skin as source of coagulase-negative staphylococcal bacteraemia? *Lancet Infect Dis* 2004; **4**: 278–286.
- 13 Wildhaber BE, Yang H, Spencer AU, Drongowski RA, Teitelbaum DH. Lack of enteral nutrition—effects on the intestinal immune system. *J Surg Res* 2005; **123**: 8–16.
- 14 Barreau F, Ferrier L, Fioramonti J, Bueno L. Neonatal maternal deprivation triggers long term alterations in colonic epithelial barrier and mucosal immunity in rats. *Gut* 2004; **53**: 501–506.
- 15 Lachman P, Yuen S. Using care bundles to prevent infection in neonatal and paediatric ICUs. *Curr Opin Infect Dis* 2009; **22**: 224–228.
- 16 Saiman L. Strategies for prevention of nosocomial sepsis in the neonatal intensive care unit. *Curr Opin Pediatr* 2006; **18**: 101–106.
- 17 O’Grady NP, Alexander M, Dellinger EP, Gerberding JL, Heard SO, Maki DG *et al*. Guidelines for the prevention of intravascular catheter-related infections. The Hospital Infection Control Practices Advisory Committee, Center for Disease Control and Prevention, U.S.. *Pediatrics* 2002; **110**: e51.
- 18 Edwards WH. Preventing nosocomial bloodstream infection in very low birth weight infants. *Semin Neonatol* 2002; **7**: 325–333.
- 19 Clark R, Powers R, White R, Bloom B, Sanchez P, Benjamin Jr DK. Prevention and study of nosocomial sepsis in the NICU. *J Perinatol* 2004; **24**: 446–453.